



S2k guidelines for the therapy of pathological scars (hypertrophic scars and keloids) – Update 2020

AWMF Registry No.: 013-030, 2020.
Guideline valid until: This guideline is valid until 31.12.2024.

Alexander Nast¹, Gerd Gauglitz^{2,3}, Kerstin Lorenz⁴, Hans-Robert Metelmann⁵, Uwe Paasch⁶, Vratislav Strnad⁷, Michael Weidmann⁸, Ricardo Niklas Werner¹, Jürgen Bauerschmitz⁹

(1) Charité - Universitätsmedizin Berlin, corporate member of Freie Universität Berlin, Humboldt-Universität zu Berlin, and Berlin Institute of Health, Department of Dermatology, Venereology and Allergology, Division of Evidence-Based Medicine (dEBM)

(2) Dermatological Practice München-Neuhausen, Munich

(3) Department of Dermatology and Allergology, Ludwig-Maximilian University, Munich

(4) Department of Visceral, Vascular and Endocrine Surgery, University Hospital Halle, Halle/Saale

(5) Department and Clinic for Oral and Maxillofacial Surgery and Plastic Surgery, University Hospital Greifswald

(6) Dermatological Practice Paasch, Gotha, Jesewitz OT Gotha

(7) Department of Radiology, University Hospital Erlangen

(8) Skin Center Am Forsterpark, Augsburg

(9) Department of Dermatology, University Hospital Erlangen

Participating medical societies

- German Dermatological Society (Deutsche Dermatologische Gesellschaft, DDG)
- German Society of Plastic, Reconstructive and Aesthetic Surgeons (Deutsche Gesellschaft der Plastischen, Rekonstruktiven und Ästhetischen Chirurgen, DGPRÄC)
- German Society for General and Visceral Surgery (Deutsche Gesellschaft für Allgemein- und Viszeralchirurgie, DGAV)
- German Society of Oral and Maxillofacial Surgery (Deutsche Gesellschaft für Mund-, Kiefer- und Gesichtschirurgie, DGMKG)
- German Society for Radiation Oncology (Deutsche Gesellschaft für Radioonkologie, DEGRO)
- German Association of Burn Treatment (Deutsche Gesellschaft für Verbrennungsmedizin, DGV)
- Professional Association of German Dermatologists (Berufsverband der Deutschen Dermatologen, BVDD)
- German Society of Laser Dermatology (Deutsche Dermatologische Lasergesellschaft, DDL)
- German Society for Dermatosurgery (Deutsche Gesellschaft für Dermatochirurgie, DGDC)

Introduction and Methods

This S2k guideline is an update of the German guideline published in 2012. Some of the passages were taken from the previous version [1].

This is the short version of the guideline. The long version can be accessed at www.awmf.org. It contains additional information e.g. on the expert committee, on use, scope and objectives, on financing, implementation and dissemination as well as management of conflicts of interest, a clinical introduction, and case reports.

The terms and symbols listed in Table 1 were used to offer standardized recommendations.

General recommendations for treating keloids and hypertrophic scars

Necessity of treatment

Hypertrophic scars and keloids are basically benign skin lesions. Any need for treatment is determined by the symptoms (e.g. pruritus/pain), by functional impairment (e.g. contraction/mechanical irritation due to elevation) or can be rationalized on aesthetic/cosmetic grounds, when a significant impact on quality of life and stigmatization can be foreseen [2]. Bock et al. developed an instrument to assess quality of life specifically for patients with hypertrophic scars and keloids. In their validation study, a severe impairment of quality of life was observed [3].

Therapeutic goals/quality indicators

Therapeutic goals must be set on an individual basis; the main consideration is to alleviate the patient's complaints. Depending on the method chosen, a clear improvement (e.g. volume reduction by 30–50 %, decrease of symptoms > 50 %, and/or sufficient patient satisfaction) should be achieved after 3–6 treatment sessions or after 3–6 months of therapy.

Table 1 Strength of recommendation – wording, symbolism and interpretation (modified after Kaminski-Hartenthaler et al. 2014).

Degree of recommendation	Wording	Symbol
Strong recommendation in favor of a measure	“is recommended“	↑↑
Weak recommendation in favor of a measure	“can be recommended“	↑
Open recommendation	“may be considered“	○
Recommendation against a measure	“is not recommended“	↓

	Recommendation	Consensus
If treatment success is not satisfactory after 3–6 sessions/3–6 months, modification of the treatment strategy (combination/switch/increase of dosage) is recommended.	↑↑	Strong consensus

None of the currently available methods for scar therapy can guarantee scar reduction or an improvement of the functional and/or cosmetic situation in all cases. The treatment method of first choice cannot be standardized for scars, as too many variables influence their development and regression (e.g. location, age and type of the scar, genetic predisposition). A combination of various treatment methods is often required to achieve success.

Classification and evaluation of treatment success

The main methods for documentation in day-to-day practice include documentation of size and thickness and photographs. Patient satisfaction and reduction of symptoms are further important considerations.

Clinical studies currently use scales such as the *Vancouver Scar Scale (VSS)*, *Patient and Observer Scar Assessment Scale (POSAS)*, *Visual Analog Scale (VAS)*, two-dimensional keloid modeling as well as mid- to high resolution B-image sonography. Subjective assessment scales are, however, of only limited use for large scars or for evaluating functional impact [4–6]. 3D imaging is also used, in particular for clinical studies.

Treatment algorithms

Algorithms for treating hypertrophic scars and keloids are depicted in Figures 1–3.

Assessment of various treatment options

Glucocorticoids

Mechanism of action

Glucocorticoids (aka glucocorticosteroids) reduce excessive scar growth by decreasing the synthesis of collagen and glycosaminoglycans, and inhibiting fibroblast proliferation. In addition to the known anti-inflammatory effect of glucocorticoids, they also inhibit iNOS transcription (iNOS, inducible form of NO synthase [7]) thus reducing collagen production in fibroblasts and inhibiting synthesis of alpha-2-macroglobulin, a collagenase inhibitor.

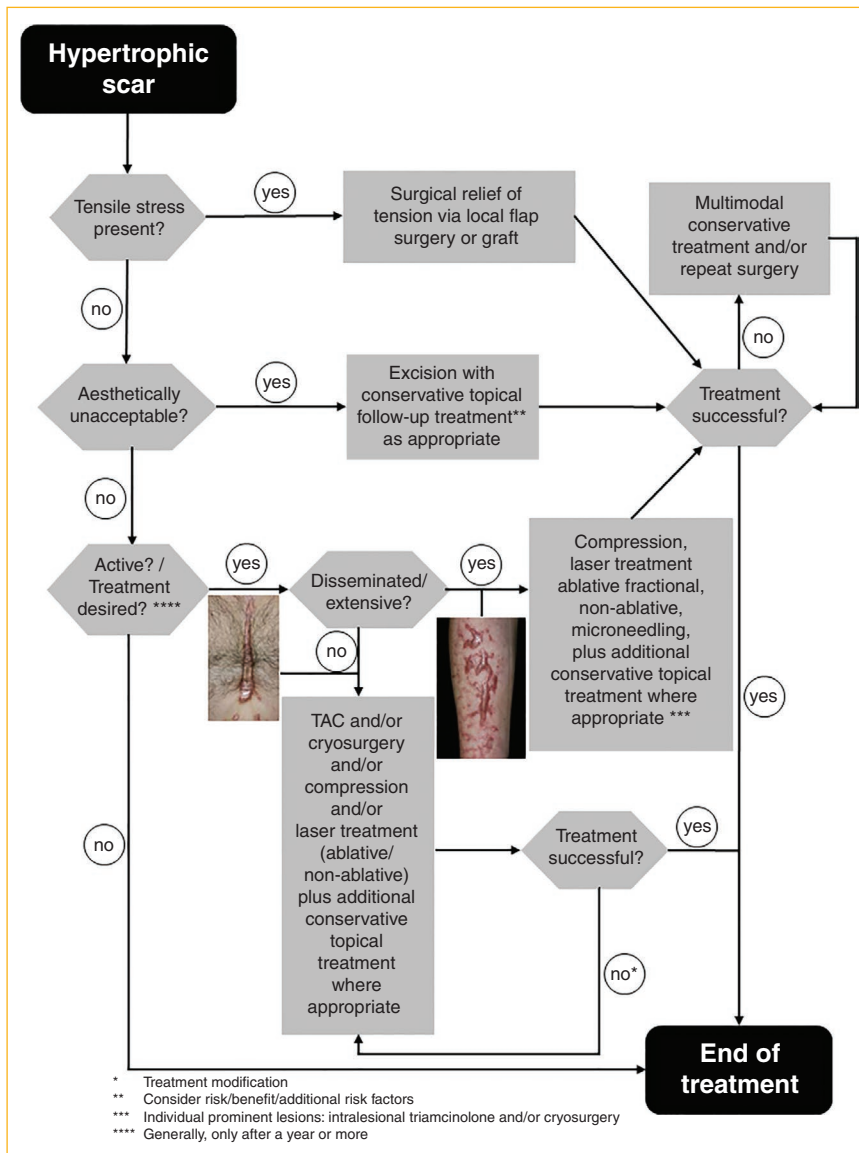


Figure 1 Treatment algorithm hypertrophic scar.

Side effects

The injections are painful. If the injection is too deep, atrophy of the subcutis may develop; if the injection is too superficial, telangiectasias and disturbed pigmentation may ensue. Whitish deposits of the crystal suspension may also occur.

Procedure for therapeutic use

Most commonly, triamcinolone acetonide (TAC) is used at a dose of 10–40 mg, at most 5 mg/cm². It can be injected as is, or diluted 1 : 2 to 1 : 4 with either NaCl 0.9 % or lidocaine. The injection must be administered in a strictly intralesional manner with a syringe that should ideally have a lo-

cking needle (Luer system). Blanching of the injected tissue indicates that infiltration is complete. Repeat injections may be administered at three to four week intervals if required. One study showed that starting with a low concentration of triamcinolone (10 mg/ml) and increasing it over time (to 20 mg/ml resp. 40 mg/ml) may reduce the risk of possible side effects and the relapse rate [8]. Superficial spray cryosurgery immediately prior to the intralesional glucocorticoid injection causes edema and facilitates infiltration [9]; it also reduces pain.

Procedure for prophylactic treatment

As a preventative measure, injection of 1 mg triamcinolone per centimeter directly into the wound margins during

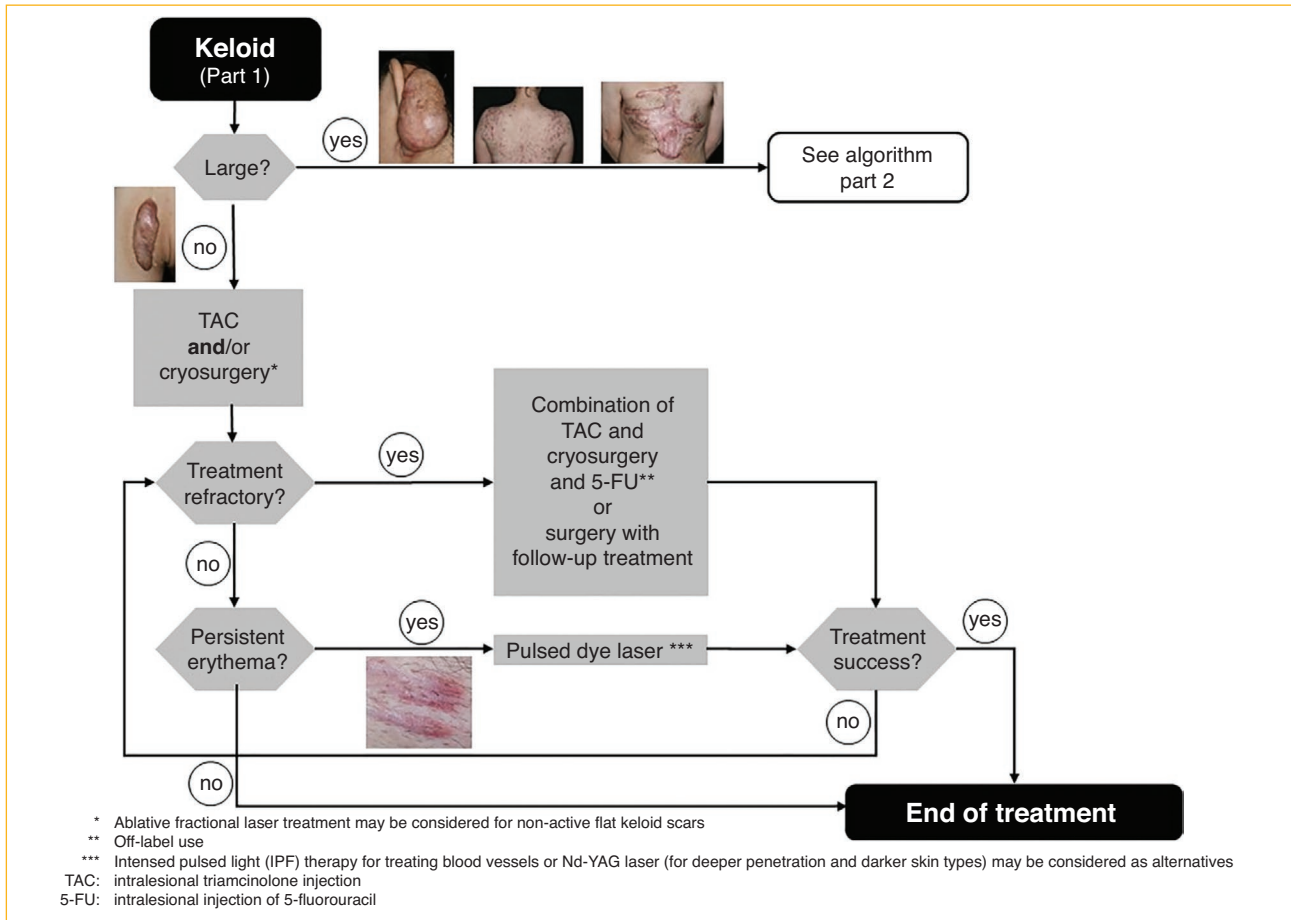


Figure 2 Treatment algorithm keloid (part I).

surgery has shown good efficacy without topical side effects [10].

Other/expert remarks

Treatment success is most likely if active scars – i.e. bright red, or subjectively symptomatic (pruritic or painful) – are treated with TAC. This is based on the mechanism of action. If there is no improvement after three therapy sessions with triamcinolone, the treatment regimen should be adapted, for example by combining it with 5-fluorouracil.

Recommended reading on efficacy and recurrence rates

Efficacy of triamcinolone acetonide in keloid treatment: a systematic review and meta-analysis. Wong TS et al. Front Med (Lausanne) 2016; 3: 71.

Glucocorticoids (Triamcinolone)	Recommendation	Consensus
Treatment of hypertrophic scars and keloids with strictly intralesional injections of glucocorticoids is recommended.	↑↑	Strong consensus
For hypertrophic scars and keloids, combination with cryosurgery is recommended.	↑↑	Strong consensus
Topical application of glucocorticoid creams or ointments alone is not recommended.	↓	Strong consensus

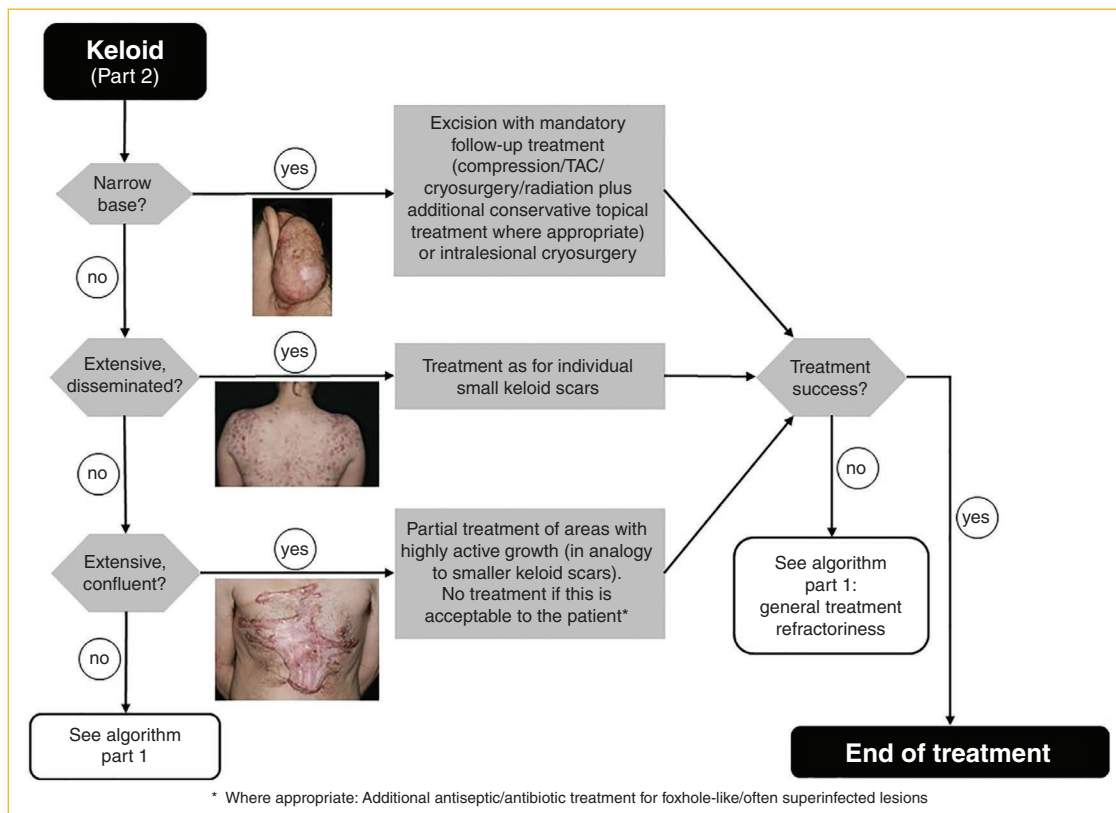


Figure 3 Treatment algorithm keloid (part II).

Glucocorticoids (Triamcinolone)	Recommendation	Consensus
Administration of glucocorticoid injections after surgical treatment of keloids is recommended.	↑↑	Strong consensus
Post-operative administration of glucocorticoid injections for the prevention of <i>de novo</i> formation of hypertrophic scars (HTS) or keloids in predisposed/at-risk patients may be considered.	o	Strong consensus

Cryosurgery

Mechanism of action

The effect is based mainly on changes in microcirculation with cold-induced alteration, thrombosis and consecutive ischemic cell death.

Side effects

Protracted healing time of about four weeks and frequent (reversible) depigmentation due to destruction of cold-sensitive melanocytes.

Procedure

There are two basic approaches:

- Short cryosurgery, especially in combination with TAC to facilitate TAC injection,
- Intense cryosurgery with total freezing of the tissue. This can be performed as spray or contact freezing or as intralesional cryosurgery.

In most cases, repeat procedures at intervals of 4–6 weeks are required until the scar has been sufficiently flattened.

Intralesional cryosurgery

Due to its various limitations, intralesional cryosurgery is only infrequently used. The required needle is a single-use medical product; its cost presents a significant hurdle for the procedure, particularly on an out-patient basis. Depending on the size of the keloid, several needles may be required, and treatment of larger keloids is time-consuming.

Under sterile conditions, nitrogen is instilled into the keloid via a double hollow needle after local anesthesia. The whole keloid is then frozen, with a halo of 3–5 mm around the lesion. Resolution of the keloid occurs within approximately four to six months (35).

Other/expert remarks

The patient should be advised to expect a blister progressing to a weeping wound; antiseptic treatment may be indicated. The next treatment session should take place only after healing of the defect caused by the previous treatment. Dark-skinned patients must also be warned of possible hyperpigmentation or hypopigmentation. Active keloids may worsen after spray cryosurgery, and in these cases, a combination e.g. with subsequent triamcinolone injections is helpful.

Recommended reading on efficacy and recurrence rates

Efficacy and safety of triamcinolone acetonide alone and in combination with 5-fluorouracil for treating hypertrophic scars and keloids: a systematic review and meta-analysis. Ren Y et al. Int Wound J 2017; 14(3): 480–7

Intralesional cryotherapy for the treatment of keloid scars: evaluating effectiveness. van Leeuwen MC et al. Plast Reconstr Surg Glob Open 2015; 3(6): e437

Cryosurgery	Recommendation	Consensus
Treatment of hypertrophic scars and keloids with cryosurgery is recommended, especially in combination with triamcinolone injections.	↑↑	Strong consensus
Cryosurgery after surgical treatment of keloids can be recommended in individual cases.	↑	Strong consensus
Postoperative cryosurgery for preventing <i>de novo</i> development of hypertrophic scars or keloids in predisposed/at-risk patients is not recommended.	↓	Strong consensus

Pressure Therapy

Mechanism of action

Localized pressure reduces capillary perfusion; it accelerates maturation of collagen and thereby flattens the scar.

Side effects

Unpleasant sensations due to heat, sweating and swelling of the limbs, dermatitis, pressure erosions and ulcerations.

Procedure

Pressure therapy, usually with elastic materials, should be started as early as possible (i.e. upon conclusion of re-epithelialization), or even preventively in patients with a predisposition for the development of pathological scars. The required pressure is 20–30 mmHg (corresponding to compression class II) and should be maintained over the whole day, i.e. 24 hours. Pressure therapy is usually performed with pressure suits or bandages, sometimes with transparent plastic masks or pressure buttons in special locations. With compression bandages made of the preferred long-stretch material, slight differences in circumference (e.g. edema) have less of an impact than with short-stretch material, so that the still tolerable maximum pressure is reached distinctly later, while on the other hand the still effective minimum pressure is less likely to be missed. With individually made pressure bandages, the applied pressure declines after about six months due to the properties of the material. Pressures may be slowly reduced over the course of the treatment period of 6–24 months. In postoperative prophylaxis, the treatment period should last at least 6–24 months.

Other/expert remarks

This treatment requires a lot of effort from the patient, and adherence is demanding for both patients and physicians.

Treatment is sometimes expensive, so the initial findings and changes over time should be documented carefully.

Recommended reading on efficacy and recurrence rates

The effects of conservative treatments on burn scars: A systematic review. Anthonissen M et al. Burns 2016; 42(3): 508–18

Pressure therapy	Recommendation	Consensus
Pressure therapy can be recommended especially in case of extensive hypertrophic scars, e.g. after burns or scalds.	↑	Strong consensus
In case of a known predisposition for hypertrophic scars or keloids after surgery or after surgical removal of pre-existing hypertrophic scars or keloids, pressure therapy in suitable locations can be recommended.	↑	Strong consensus

Surgical aspects of treating keloids and hypertrophic scars

Mechanism of action

Hypertrophic scars and keloids are fibroproliferative skin diseases of varying duration and intensity of inflammation. They are caused by genetic, systemic, and topical risk factors. The type of damage to the reticular dermis, such as thermal damage and impaired healing with prolonged inflammation, may result in disrupted scarring. Mechanical tension plays a major role in this process. This offers an opportunity for surgical prevention and intervention, since genetic and systemic causes cannot currently be influenced.

Side effects

Surgical treatment itself carries a high risk of recurrence, especially in case of keloids, resulting in lesions that are often larger than the original lesion. An indication for surgery should therefore be declared with caution, except in cases of small hypertrophic scars.

In addition, the normal risks of skin surgery need to be considered.

Procedure

Prevention of hypertrophic scars/keloids during surgery

Undisturbed wound healing and avoidance of mechanical tension are important particularly in patients with a history

of keloid formation. Measures to achieve this include: atraumatic surgical techniques, multilayer suturing techniques that avoid tension, use of materials suitable for the location, use of zig-zag plasty (W, Z) in incisions crossing joints, and flap surgery in case of excisions to relieve tension. The indication for surgery must be carefully verified.

Optimal post-operative care with the aim of rapid healing reduces the risk for keloids resulting from a prolonged inflammatory phase. Epidermal wound healing requires 7–10 days, but this is insufficient for dermal healing and stabilization of the scar. Since the healing dermis reaches 90 % of its former stability only after three months, a reduction of mechanical tension through rest, butterfly bandages, silicone sheeting or compression is recommended over a longer period. Revision surgery for hypertrophic scars usually yields satisfactory results, but the recurrence rate for keloids is 45–100 % if only surgery is employed.

Surgical techniques

Any kind of plastic surgery may be used – from primary wound closure to flap techniques, if the timing is considered for hypertrophic scars and surgery is combined with an effective adjuvant treatment for keloids, especially in case of recurrence.

Z-plasty is suitable for relieving linear contractures and tension over joints. Long, longitudinal scar tracts are converted into shorter sections within the relaxed skin tension lines (RSTL) and extended depending on the angles. This reduces mechanically induced inflammation. In addition, shorter scar sections mature more rapidly. W-plasty is suitable for flat areas on the face but not over expression lines or joints. Scars should be excised completely. Scar tissue in the flap tips will increase the risk of necrosis. As opposed to scars, healthy skin can stretch and relieve tension.

Skin grafts are suitable for replacing large areas of scarred skin, but they are themselves prone to developing secondary contractures. Very thin “isotopic” split skin grafts, harvested in the area of the scar before excision of the dermal scars and subsequently re-positioned *in loco*, may be used for extensive hypertrophic scars. There is a recent description of this technique for scars after self-injury [11].

Flap surgery is superior for relieving scar contractures since – as opposed to grafts – flaps have a natural tendency to relax. Apart from local flap surgery, other techniques include pedicled flaps, free flaps, distant flaps and expanders. Flap surgery is also required for reconstruction of large defects after resection of extensive keloids which are themselves usually recurrences after previous surgery. Any keloid risk at the donor site should be minimized by using highly effective adjuvant treatments such as postoperative radiation therapy (see the relevant chapter below). Dermal suturing is unable to

achieve tension relief in the reticular dermis, though this is important for preventing recurrence. For this purpose, fascial sutures can be added for the trunk after block-like deep resection of the subcutaneous tissue down to the muscles, and broad subfascial mobilization [12–14].

Extramarginal versus intramarginal excision

In view of genetic alterations and local recurrence after excision, keloids may be said to show neoplastic properties. They have an inactive center and a progressive and in part even infiltrative margin. This suggests that extramarginal excision is more prudent than intramarginal excision. Recent studies have also shown that histologically incomplete excision results in increased recurrence rates [15, 16].

Follow-up treatment

Long-term care and instruction of the patient are essential for achieving lasting success after surgery. Healing disorders, e.g. due to radiation, must be treated. Timely immobilization, pressure/compression and butterfly bandages may assist in tension relief. Conservative treatment (see the respective chapters) can supplement recurrence prophylaxis.

Other, expert remarks

Lipotransfer and treatment with fatty tissue-derived mesenchymal stem cells are still at an experimental stage. It is hoped that these will have anti-inflammatory and anti-fibrotic effects; this is to be systematically addressed in preclinical studies [17].

Recommended reading on efficacy and recurrence rates

Keloid excision and adjuvant treatments. A network meta-analysis. Sittos C et al. Ann Plast Surg 2019; 83: 154–62

Treatment (hypertrophic scars)	Recommendation	Consensus
Surgical treatment of hypertrophic scars without tensile stress or cosmetic disfigurement that have been present for less than one year is not recommended.	↓	Strong consensus

Timely surgical treatment of scar contractures over joints or in mobile areas with reduced function or cosmetic disfigurement is recommended.	↑↑	Strong consensus
Suitable plastic surgery techniques for relieving tension are recommended. Grafts are recommended if tension-relieving surgery is not feasible.	↑↑	Strong consensus

Surgical treatment (Keloids)	Recommendation	Consensus
For keloids, neither an exclusively surgical treatment, nor ablative monotherapy with a CO ₂ laser or an Er:YAG laser can be recommended.	↓	Strong consensus
Surgical treatment of keloids can be recommended after unsuccessful conservative treatment.	↑	Strong consensus
It is strongly recommended that adjuvant treatments and their procedures be planned in advance when excision of keloids is envisaged (see other chapters).	↑↑	Strong consensus
According to our current knowledge of keloid biology and studies on recurrence that depend on the histological resection status, extramarginal excision (Ro excision) is recommended.	↑↑	Strong consensus
Intramarginal excision may be considered if extramarginal excision is not feasible.	o	Strong consensus

It is recommended that long-term multimodal follow-up treatment should be performed. The patient needs to receive detailed information on the necessity of these procedures beforehand.

↑↑ Strong consensus

Fractional ablative laser treatment

Laser devices

Ablative lasers (CO₂, Er:YAG, Er:YSGG and thulium lasers) can be employed either in circumscribed areas, or in a fractional manner. The latter method leaves some vital tissue between the ablation zones, ensuring specific efficacy with a low rate of side effects.

Mechanism of action

A specific sequence of spatiotemporal wound healing, involving heat shock proteins from the epidermis surrounding the ablation channels, leads to epidermal and dermal restructuring. This results in normalization of cellular and connective tissue structures, vessels, nerves, and possibly even the locoregional immune system. When these lasers are used to treat scars, in addition to scar thickness, pruritus, erythema, density, and pigmentation often improve. This can result, for example, in the improvement of the functional aspect of contractures.

Side effects

Ablative laser treatment always causes *bronzing*, and at high energies can also produce erosions, weeping, crusts, and persistent erythema. Depigmentation and hyperpigmentation are usually more intense and more persistent after CO₂ laser treatment, since Er:YAG lasers hardly generate any heat. Viral or bacterial superinfections are also possible complications.

Procedure

AFXL is initiated directly after suture removal or as early as possible. Treatment series of at least six sessions at four-week intervals are to be recommended. This is followed by the decision to either conclude the treatment or to add further sessions.

Ablation channels created in the scar tissue may also be utilized to administer medications (laser assisted drug delivery [LADD]).

Other/expert remarks

Fractional ablative laser treatment is technically simple and can be performed rapidly. Either alone or combined with laser assisted drug delivery (LADD) with TAC/5-fluorouracil, the method usually results in the improvement of one or more aspects of the scar (pruritus, erythema, density, pigmentation, or thickness) as well as in an improvement of the subjective cosmetic appearance.

Recommended reading on efficacy and recurrence rates

Treatment of keloid scars using light-, laser- and energy-based devices: a contemporary review of the literature. Forbat E et al. Lasers Med Sci 2017; 32(9): 2145–54

Ablative fractional laser treatment	Recommendation	Consensus
Treatment of hypertrophic scars with a fractional ablative laser, either as monotherapy or in combination with laser-assisted drug delivery, can be recommended. This applies to hypertrophic scars after burns/scalds in particular.	↑	Strong consensus
Treatment of active keloids with fractional ablative lasers is not recommended.	↓	Strong consensus
Treatment of inactive, flat keloids with ablative lasers in combination with triamcinolone injection or with laser-assisted drug delivery may be considered.	○	Strong consensus
A recommendation for or against the use of fractional ablative lasers to prevent hypertrophic scars or keloids after surgery cannot currently be given due to the scarcity of available data.	Statement	Strong consensus

Non-ablative laser treatment

Pulsed dye laser

Mechanism of action

Laser coagulation reduces vascular supply, resulting in hypoperfusion and hypoxia, and ensuing regression of pathological scars. There have also been reports of reduced expression of Transforming Growth Factor (TGF) β 1 and fibroblast proliferation, up-regulation of MMP-13 (collagenase 3), induction of fibroblast apoptosis, and up-regulation of ERK (extracellular signal-regulated kinase) and p38-MAP kinase activity after use of flash lamp-pumped pulsed dye laser (FPDL) [18, 19].

Side effects

A purpura often develops that can then persist for up to 14 days. Depending on the energy density deployed by the laser and on the patient's skin pigmentation, blisters and crusts may also occur. Persistent hyperpigmentation is more frequent in persons with a dark skin type but is seen more rarely at a wavelength of 595 nm than at 585 nm.

Procedure

Depending on the patient's skin pigmentation, treatment with a 585 nm FPDL is usually performed with an energy density of approximately 5.5–7.5 J/cm² and a spot diameter of 5–7 mm, or about 4.5–5.5 J/cm² with spot sizes of 10 mm. At least two treatment sessions at an interval of about six to eight weeks are recommended.

Nd:YAG laser: (1064 nm)

Mechanism of action

Damage to the deep dermal vessels results in a reduction of fibroblast collagen production.

Side effects

See pulsed dye laser; this treatment is also very painful.

Procedure

Treatment protocols remain insufficiently standardized; treatment "overlaps" are to be avoided.

Intensed pulsed light

Mechanism of action

The mechanism of action is probably the same as for pulsed dye lasers with a vascular filter.

Side effects

See pulsed dye laser, there is a danger of deterioration in case of excessive thermic damage (particularly for skin types V and VI).

Procedure

Treatment protocols remain insufficiently standardized and depend strongly on the laser used.

Other/expert remarks

Several treatment sessions at four-week intervals using moderate settings show the best and most sustained results.

Recommended reading on efficacy and recurrence rates

Treatment of keloid scars using light-, laser- and energy-based devices: a contemporary review of the literature. Forbat E et al. Lasers Med Sci 2017; 32(9): 2145–54

Non-ablative laser treatment	Recommendation	Consensus
Treatment with pulsed dye lasers can be recommended, particularly for reducing erythema e.g. in case of recent, strongly vascularized, erythematous hypertrophic scars and keloids.	↑	Strong consensus
Nd:YAG lasers with their deeper penetration may be considered as an alternative for reducing erythema in case of thicker keloids and darker skin types.	o	Strong consensus
The <i>intense-pulsed-light</i> (IPL) technique for treating blood vessels may be considered as an alternative to pulsed dye lasers.	o	Strong consensus
Fractional non-ablative lasers (e.g. erbium glass lasers) can be recommended for treating hypertrophic scars, in particular after burns/scalds.	↑	Strong consensus

Treatment of flat, inactive keloids with non-ablative lasers (e.g. erbium glass laser) in combination with triamcinolone injections may be considered.	o	Strong consensus
--	---	------------------

Microneedling

Mechanism of action

In microneedling, the skin is pierced with many small needles. The resulting microtrauma triggers a wound healing cascade that leads to skin restructuring.

Side effects

There is a risk of infection, allergic or irritative dermatitis, and of developing hyperpigmentation. There have been isolated reports of granulomas after microneedling as well as of the formation of hypertrophic scars in a *tram track* pattern [20, 21].

Procedure

Needling is carried out with needles of 1.5 to 3 mm length. These can be attached to a roll or a stamp and are applied to the skin. Treatment is usually performed after application of a local anaesthetic cream, or even under intubation anesthesia in the case of extensive lesions. The puncture holes left by the needles in the scar tissue can be used to administer medications (needling-assisted drug delivery).

Other/expert remarks

Microneedling carries a lower risk for hyperpigmentation than the use of lasers for similar indications. There are only a handful of published studies on the efficacy of microneedling for hypertrophic scars, and even these have relevant methodic limitations. Positive experiences have been reported for hypertrophic scars after burns/scalds or similar.

Recommended reading on efficacy and recurrence rates

Microneedling: A Comprehensive Review. Hou A et al. Dermatologic Surgery 2017; 43(3): 321–39

Microneedling	Recommendation	Consensus
Microneedling alone or in combination with needling-assisted drug delivery for treating hypertrophic scars, especially after burns/scalds, can be recommended.	↑	Strong consensus
Microneedling is not recommended for treating keloids.	↓	Strong consensus

Radiation therapy

Mechanism of action

The effect of ionizing radiation on pathological keloid scars is based on two main principles [1, 22]:

1. Radiation has a direct antiproliferative effect on fibroblasts and myofibroblasts, due to inhibition of cell proliferation, delayed mitosis and mitosis-induced cell death. These effects depend on the single and overall dose of radiation, the influence of fractioning, the oxygen effect, and the different biological effects of various types of radiation.
2. Radiation also displays a direct anti-inflammatory effect via lymphocyte apoptosis, induction of differentiation of fibroblasts/fibrocytes, effects on the cell membrane, endothelial cells and macrophages/monocytes, as well as effects on leukocyte adhesion (ICAM) and oligonucleotides (NF-κB). An adequate dose of radiation will lead to less excessive fibroblast formation and to inhibition of keloid development without delaying wound healing.

Procedure

Optimally, postoperative irradiation after excision of a keloid should commence within seven hours, and within 24 hours at the latest. Irradiation within seven hours achieves the best results [23, 24].

HDR brachytherapy/LDR brachytherapy

After keloid excision, a plastic mini-catheter is positioned in the deepest base of the surgical scar and affixed there. If possible, this catheter should not be implanted deeper than one centimeter under the skin. For large keloids, more than

one mini-catheter may be used. Note that the direction of the catheter should be exactly the same as the direction of the scar. After closing the scar with non-absorbable sutures, a compression dressing should be applied (if possible), leaving one end of the catheter free to allow for connection to an afterloading device.

Percutaneous radiation therapy

A linear accelerator with 7 MV fast electrons and 5 mm foil is preferred for treatment. An overall dose of 12–14 Gy is recommended in three to four fractions once or twice a day. This should be performed within one week after surgery.

Side effects

Conventional percutaneous postoperative radiation therapy may lead to mild erythema and scaling in the area of the scar, lasting for about 3–4 weeks. Chronic side effects after percutaneous radiation therapy include hyperpigmentation and depigmentation, dry skin, and telangiectasia; however these are almost exclusively observed after overall doses of ≥ 20 Gy. When using HDR brachytherapy with an overall dose of 12–14 Gy, visible, adverse effects on the skin are very rare.

In no study has a connection been found between irradiation of keloid scars and secondary malignancies [24–29].

Other/expert remarks

Keloid excision with subsequent HDR brachytherapy offers the lowest recurrence rates (10 % on average). Other types of radiation therapy show higher recurrence rates; however there is a lack of high-quality studies on this topic

Several analyses, overviews, and meta-analyses of available published data provide the following important facts [23, 24, 30, 31]:

1. Techniques utilizing adjuvant percutaneous radiation therapy result in 1.2–2.0 times higher rates of keloid recurrence than techniques utilizing brachytherapy.
2. HDR brachytherapy offers the lowest recurrence rates (average 10.5 % ± 15, range: 0–44), followed by LDR brachytherapy (average 21.3 % ± 2.1, range: 19.4–23.6) and percutaneous radiation therapy (average 22.2 % ± 16, range: 0–72).
3. It is recommended that the time interval between keloid excision and irradiation be kept as short as possible. There is a difference in keloid recurrence rates after postoperative irradiation depending on whether radiation was started within 7 hours, within 24 hours, or after 24 hours. In studies where radiation therapy (brachytherapy) was initiated within seven hours, recurrence rates of only 2.3 % were observed [23].

Treatment should preferably be performed in specialized clinics with an interdisciplinary team of physicians (dermatology, plastic surgery, radiation therapy).

After keloid excision and adjuvant radiation therapy, the usual postoperative procedures and special measures for tension-free wound care should be observed, just as with other methods for keloid prevention.

Recommended reading on efficacy and recurrence rates

Optimizing radiotherapy for keloids: a meta-analysis systematic review comparing recurrence rates between different radiation modalities. Mankowski P et al. Annals of plastic surgery 2017; 78: 403–11

Surgical Excision with Adjuvant Irradiation for Treatment of Keloid Scars: A Systematic Review. van Leeuwen MC et al. Plast Reconstr Surg Glob Open 2015; 3: e440.

Leitlinien in der Strahlentherapie. Strahlentherapie gutartiger Erkrankungen fachgruppenspezifische evidenzbasierte S2e-Leitlinie der Deutschen Gesellschaft für Radioonkologie (DEGRO). Version 2.0 vom 02.11.2018

Radiation therapy	Recommendation	Consensus
Adjuvant radiation therapy after keloid excision is recommended in cases of keloid recurrence.	↑↑	Strong consensus
Adjuvant radiation therapy after keloid excision is recommended for keloids that are either large or difficult to treat with other methods.	↑↑	Strong consensus
Adjuvant radiation therapy after keloid excision may be considered for smaller keloids after careful weighing of risk factors.	○	Strong consensus
HDR brachytherapy is recommended as the preferable method for adjuvant radiation therapy.	↑↑	Strong consensus
Primary monotherapy of hypertrophic scars and keloids with radiation is not recommended.	↓	Strong consensus

Silicone sheeting and silicone gel

Mechanism of action

The mechanism of action for silicone gels has not been fully clarified. Occlusion, and the resulting increased moisturization, particularly of the stratum corneum, is believed to cause a signaling effect on fibroblasts via cytokine release from keratinocytes [32]. After 24 weeks of silicone application, reduced numbers of mast cells and a reduction in the increased expression of Fas antigen from intralesional fibroblasts were observed [33].

Side effects

Occlusion may result in folliculitis in sporadic cases.

Procedure

Silicones are available as gels, creams, pads, sheets and foils. Typical use is 12–24 h/day over a period of twelve to 24 weeks. If they are used preventively after surgery, treatment may begin shortly after suture removal. When treating open wounds, preventive use should be delayed until the wound has been completely epithelialized. Treatment usually lasts for several weeks to months.

Other/expert remarks

Evidence for the benefits of silicone preparations for preventing hypertrophic scars and keloids is weak [34]. There are some indications for a benefit in the treatment of hypertrophic scars and keloids in terms of scar thickness and color [34].

Recommended reading on efficacy and recurrence rates

Silicone gel sheeting for preventing and treating hypertrophic and keloid scars. O'Brien L et al. *Cochrane Database Syst Rev* 2013; 9: CD003826

Review of silicone gel sheeting and silicone gel for the prevention of hypertrophic scars and keloids. Hsu KC et al. *Wounds* 2017; 29(5): 154–8

Silicone sheeting and silicone gel	Recommendation	Consensus
Use of silicone preparations may be considered especially as an add on in the treatment of active hypertrophic scars.	o	Strong consensus

Postoperative use of silicone preparations for preventing <i>de novo</i> formation of hypertrophic scars or keloids in patients with risk factors or predisposition, as well as after surgical treatment of hypertrophic scars or keloids, can be recommended.	↑	Strong consensus
--	---	------------------

Extractum cepae (onion extract)

Mechanism of action

Extractum cepae has anti-inflammatory and bactericidal effects and inhibits fibroblast proliferation. Induction of matrix-metalloproteinase 1 (MMP-1) [35] and inhibition of the TGFβ/Smad signaling pathway have been discussed as possible mechanisms of action [36].

Side effects

Intolerance of the ingredients can lead to allergic contact dermatitis.

Procedure

In general, an external application should be done several times a day, and ideally with light massaging into the scar tissue. For old, indurated scars, occlusion after application may be considered. If used preventively after surgery, treatment may commence shortly after the sutures have been removed. When treating open wounds, preventive use should be delayed until the wound has been completely epithelialized. Treatment usually lasts for several weeks to months.

Other/expert remarks

Preparations with *extractum cepae* contain other ingredients as well. Onion extract may cause irritation and should be used with caution, particularly on the face or in small children.

Recommended reading on efficacy and recurrence rates

Systematic reviews on the benefits of *extractum cepae* for the prevention or treatment of hypertrophic scars and keloids are not available; the existing evidence from controlled clinical studies is limited.

Extractum cepae (onion extract)	Recommendation	Consensus
Treatment of active hypertrophic scars with combination products containing <i>extractum cepae</i> (onion extract) may be considered as an add on treatment.	o	Strong consensus
Use of combination products containing <i>extractum cepae</i> (onion extract) may be considered for postoperative prevention of <i>de novo</i> formation of hypertrophic scars or keloids, as well as for prevention of recurrence after surgical treatment of hypertrophic scars or keloids.	o	Strong consensus

5-fluorouracil and bleomycin

Mechanism of action

The pyrimidine analog 5-fluorouracil (5-FU) inhibits fibroblast proliferation.

Side effects

Burning pain on injection, hyperpigmentation, skin irritation, ulcerations.

Procedure

Application is usually every four weeks at a concentration of 50 mg/ml and a maximum overall dose of 50–150 mg per treatment [37]. As with TAC, 5-FU is injected strictly intralesionally with a syringe that ideally has a locking needle. Various studies conducted in recent years have shown that a combination of 5-FU and TAC either at a 9 : 1 or 3 : 1 ratio seems to be superior to either medication as monotherapy.

Other/expert remarks

This is an off-label treatment, and the patient must be informed accordingly. Treatment with 5-FU shows good response rates, especially when combined with other therapeutic options. Local side effects are less pronounced than with triamcinolone, and so it can be used in ‘cortisone-sensitive’ areas [38, 39].

In some countries, bleomycin is used instead of 5-FU, particularly in dark-skinned patients. Use of bleomycin is however extremely rare in Germany. As compared with 5-FU, the risk of skin ulcerations in dark-skinned patients is said to be lower with bleomycin. The substance is injected directly into the scar tissue at a concentration of 1.5 IU/ml.

Neither 5-FU nor bleomycin is approved for treating hypertrophic scars and keloids, which constitutes a limiting factor for primary use.

Recommended reading on efficacy and recurrence rates

Efficacy and safety of triamcinolone acetonide alone and in combination with 5-fluorouracil for treating hypertrophic scars and keloids: a systematic review and meta-analysis. Ren Y et al. *Int Wound J* 2017; 14(3): 480–7

5-Fluorouracil	Recommendation	Consensus
Treatment of otherwise refractory hypertrophic scars with 5-FU (<i>off label</i>) may be considered.	o	Strong consensus
Treatment of otherwise refractory keloids with 5-FU (<i>off label</i>) can be recommended.	↑	Strong consensus
Treatment with 5-FU (<i>off label</i>) may be considered for preventing <i>de novo</i> formation of hypertrophic scars or keloids in risk patients, and for preventing recurrence after surgical treatment.	o	Strong consensus

Other therapeutic approaches

Calcium channel blockers	Recommendation	Consensus
A recommendation for or against the use of calcium channel blockers for prevention or treatment of hypertrophic scars or keloids cannot currently be issued due to the scarce and often contradictory nature of available data.	Statement	Strong consensus

Imiquimod [40]	Recommendation	Consensus
Imiquimod is not recommended for either prevention or treatment of hypertrophic scars or keloids.	↓	Strong consensus

Hyaluronidase	Recommendation	Consensus
A recommendation for or against the use of hyaluronidase for prevention or treatment of hypertrophic scars or keloids cannot currently be issued due to the scarcity of available data.	Statement	Strong consensus

Plasma	Recommendation	Consensus
A recommendation for or against the use of plasma for prevention or treatment of hypertrophic scars or keloids cannot currently be issued due to the scarcity of available data.	Statement	Strong consensus

Conflict of interest

See long version of this guideline at www.awmf.org.

Correspondence to

Prof. Dr. med. Alexander Nast
 Department of Dermatology, Venereology and Allergology
 Division of Evidence-based Medicine (dEBM)
 Charité – Universitätsmedizin Berlin
 Charitéplatz 1
 10117 Berlin
 Germany
 E-mail: debmo1@charite.de

References

- Nast A, Eming S, Fluhr J et al. German S2k guidelines for the therapy of pathological scars (hypertrophic scars and keloids). *J Dtsch Dermatol Ges* 2012; 10: 747–62.
- Balci DD, Inandi T, Dogramaci CA, Celik E. DLQI scores in patients with keloids and hypertrophic scars: a prospective case control study. *J Dtsch Dermatol Ges* 2009; 7: 688–92.
- Bock O, Schmid-Ott G, Malewski P, Mrowietz U. Quality of life of patients with keloid and hypertrophic scarring. *Arch Dermatol Res* 2006; 297: 433–8.
- Fearmonti R, Bond J, Erdmann D, Levinson H. A review of scar scales and scar measuring devices. *Eplasty* 2010; 10: e43.
- Perry DM, McGrouther DA, Bayat A. Current tools for noninvasive objective assessment of skin scars. *Plast Reconstr Surg* 2010; 126: 912–23.
- Sebastian G, Hackert I, Stein A, Aschoff R. Möglichkeiten zur Objektivierung der Effizienz der Kryotherapie bei Keloiden. In: Koller J, Hutner H: Fortschritte der operativen und onkologischen Dermatologie. Berlin, Wien: Blackwell, 2000: 192–7.
- Schaffer MR, Efron PA, Thornton FJ et al. Nitric oxide, an autocrine regulator of wound fibroblast synthetic function. *J Immunol* 1997; 158: 2375–81.
- Anthony ET, Lemonas P, Navsaria HA, Moir GC. The cost effectiveness of intralesional steroid therapy for keloids. *Dermatol Surg* 2010; 36: 1624–6.
- Ceilley RI, Babin RW. The combined use of cryosurgery and intralesional injections of suspensions of fluorinated adrenocorticosteroids for reducing keloids and hypertrophic scars. *J Dermatol Surg Oncol* 1979; 5: 54–6.
- Danielsen PL, Rea SM, Wood FM et al. Verapamil is less effective than triamcinolone for prevention of keloid scar recurrence after excision in a randomized controlled trial. *Acta Derm Venereol* 2016; 96: 774–8.
- Goutos I, Ogawa R. Isotopic split-skin graft for resurfacing of deliberate self-harm scars. *Plast Reconstr Surg Glob Open* 2018; 6: e1801.
- Jahn J, Strnad V, Bauerschmitz J. Postoperative Iridium 192 Brachytherapie zur Behandlung einesmonströsen Keloides nach Exzision und Wundverschluss mittelsdoppelter Rotationsschlappenplastik nach Webster. *J Dtsch Dermatol Ges* 2010; 8: 565.
- Ogawa R. Surgery for scar revision and reduction: from primary closure to flap surgery. *Burns Trauma* 2019; 7: 7.
- Arima J, Dohi T, Kuribayashi S et al. Z-plasty and postoperative radiotherapy for anterior chest wall keloids: an analysis of 141 patients. *Plast Reconstr Surg Glob Open* 2019; 7: e2177.
- Tan KT, Shah N, Pritchard SA et al. The influence of surgical excision margins on keloid prognosis. *Ann Plast Surg* 2010; 64: 55–8.
- Chong Y, Kim CW, Kim YS et al. Complete excision of proliferating core in auricular keloids significantly reduces local recurrence: A prospective study. *J Dermatol* 2018; 45: 139–44.
- Chai CY, Song J, Tan Z et al. Adipose tissue-derived stem cells inhibit hypertrophic scar (HS) fibrosis via p38/MAPK pathway. *J Cell Biochem* 2019; 120: 4057–64.
- Kuo YR, Wu WS, Jeng SF et al. Activation of ERK and p38 kinase mediated keloid fibroblast apoptosis after flashlamp pulsed-dye laser treatment. *Lasers Surg Med* 2005; 36: 31–7.
- Kuo YR, Wu WS, Jeng SF et al. Suppressed TGF-beta1 expression is correlated with up-regulation of matrix metalloproteinase-13 in keloid regression after flashlamp pulsed-dye laser treatment. *Lasers Surg Med* 2005; 36: 38–42.
- Cary JH, Li BS, Maibach HI. Dermatotoxicology of microneddes (MNs) in man. *Biomed Microdevices* 2019; 21: 66.

- 21 Eisert L, Zidane M, Waigandt I et al. Granulomatous reaction following microneedling of striae distensae. *J Dtsch Dermatol Ges* 2019; 17: 443–5.
- 22 Leitlinien in der Strahlentherapie. Strahlentherapie gutartiger Erkrankungen, Fachgruppenspezifische evidenzbasierte S2e-Leitlinie der Deutschen Gesellschaft für Radioonkologie (DEGRO), Version 2.0. Available from <https://www.degro.org/wp-content/uploads/2018/11/S2-Leitlinie-Strahlentherapie-gutartiger-Erkrankungen-update-2018-Endversion.pdf> [Last accessed August 8, 2020].
- 23 van Leeuwen MC, Stokmans SC, Bulstra AE et al. High-dose-rate brachytherapy for the treatment of recalcitrant keloids: a unique, effective treatment protocol. *Plast Reconstr Surg* 2014; 134: 527–34.
- 24 van Leeuwen MC, Stokmans SC, Bulstra AE et al. Surgical excision with adjuvant irradiation for treatment of keloid scars: a systematic review. *Plast Reconstr Surg Glob Open* 2015; 3: e440.
- 25 Cheraghi N, Cognetta A, Jr, Goldberg D. Radiation therapy for the adjunctive treatment of surgically excised keloids: a review. *J Clin Aesthet Dermatol* 2017; 10: 12–5.
- 26 Goutos I, Ogawa R. Brachytherapy in the adjuvant management of keloid scars: literature review. *Scars Burn Heal* 2017; 3: 2059513117735483.
- 27 Ogawa R, Yoshitatsu S, Yoshida K, Miyashita T. Is radiation therapy for keloids acceptable? The risk of radiation-induced carcinogenesis. *Plast Reconstr Surg* 2009; 124: 1196–201.
- 28 De Lorenzi F, Tielemans HJ, van der Hulst RR et al. Is the treatment of keloid scars still a challenge in 2006? *Ann Plast Surg* 2007; 58: 186–92.
- 29 Kal HB, Veen RE, Jurgenliemk-Schulz IM. Dose-effect relationships for recurrence of keloid and pterygium after surgery and radiotherapy. *Int J Radiat Oncol Biol Phys* 2009; 74: 245–51.
- 30 Mankowski P, Kanevsky J, Tomlinson J et al. Optimizing radiotherapy for keloids: a meta-analysis systematic review comparing recurrence rates between different radiation modalities. *Ann Plast Surg* 2017; 78: 403–11.
- 31 Escarmant P, Zimmermann S, Amar A et al. The treatment of 783 keloid scars by iridium 192 interstitial irradiation after surgical excision. *Int J Radiat Oncol Biol Phys* 1993; 26: 245–51.
- 32 Mustoe TA. Evolution of silicone therapy and mechanism of action in scar management. *Aesthetic Plast Surg* 2008; 32: 82–92.
- 33 Eishi K, Bae SJ, Ogawa F et al. Silicone gel sheets relieve pain and pruritus with clinical improvement of keloid: possible target of mast cells. *J Dermatolog Treat* 2003; 14: 248–52.
- 34 O'Brien L, Pandit A. Silicon gel sheeting for preventing and treating hypertrophic and keloid scars. *Cochrane Database Syst Rev*. 2006: CD003826.
- 35 Cho JW, Cho SY, Lee SR, Lee KS. Onion extract and quercetin induce matrix metalloproteinase-1 in vitro and in vivo. *Int J Mol Med* 2010; 25: 347–52.
- 36 Phan TT, Lim IJ, Chan SY et al. Suppression of transforming growth factor beta/smad signaling in keloid-derived fibroblasts by quercetin: implications for the treatment of excessive scars. *J Trauma* 2004; 57: 1032–7.
- 37 Gupta S, Kalra A. Efficacy and safety of intralesional 5-fluorouracil in the treatment of keloids. *Dermatology* 2002; 204: 130–2.
- 38 Hietanen KE, Jarvinen TA, Huhtala H et al. Treatment of keloid scars with intralesional triamcinolone and 5-fluorouracil injections – a randomized controlled trial. *J Plast Reconstr Aesthet Surg* 2019; 72: 4–11.
- 39 Srivastava S, Patil A, Prakash C, Kumari H. Comparison of intralesional triamcinolone acetonide, 5-fluorouracil, and their combination in treatment of keloids. *World J Plast Surg* 2018; 7: 212–9.
- 40 Klotz T, Munn Z, Aromataris EC, Greenwood JE. Imiquimod to prevent keloid recurrence postexcision: A systematic review and meta-analysis. *Wound Repair Regen* 2020; 28(1): 145–56.